

PATIENT

Stella Shaw

SPECIES

Canine

BREED

DSH

SEX

Intact Female

AGE

7½ years

WEIGHT

105 #

INTERPRETED BY

Remo Lobetti, BVSc,
MMedVet (Med),
PhD, Dipl. ECVIM

**IMAGING
PERFORMED BY**

Lara Wiseman, DVM

HOSPITAL NAME

Boca Midtowne
Animal Hospital

REFERRING VET

Dr Boazman

INVOICE

302929

DATE

4/27/22

PRESENTING CLINICAL SIGNS

History: Chronic intermittent vomiting that is becoming progressive, picky eater, difficulty in getting up on the hindquarters.

Physical Examination: Pyrexia (103.3), lethargy, popliteal lymphadenopathy, small mass on the right hip (cytology pending).

Urinalysis: Pending.

CBC: Pending.

Serum Biochemistry: Pending.

Radiographic Findings: Pending.

ULTRASONOGRAPHIC EXAMINATION OF THE ABDOMEN

Urinary System

Full urinary bladder with a normal appearance and thickness of the wall. Normal anechoic urine with no sediment or uroliths evident.

Normal trigone area, proximal urethra (0.4 cm), and iliac blood vessels.

Normal iliac lymph nodes (2.7 cm). Ureters not visualized.

Normal renal size (left 7.2 cm, right 8.1 cm), echogenic appearance, cortico-medullary differentiation, pelvis, and capsule.

Reproductive System

Visible uterine body (0.8 cm), right horn (0.5 cm) and left horn (0.6 cm) containing small amount of fluid. Normal shape, size and appearance of the right ovary (1.7 cm).

Adrenal Glands

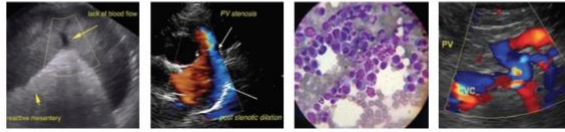
Normal shape, echogenic appearance, position, and size. Left 0.69 cm, right 0.59 cm

Spleen

Normal size (1.8 cm) and echogenic appearance. Smooth homogenous parenchyma, smooth curvi-linear capsule, and normal vasculature. No evidence of inflammatory, neoplastic, infarction, or infiltrative changes noted.

Liver

Normal size, echogenic appearance, and portal markings. No nodules or masses evident. Small gall bladder containing normal anechoic bile. Normal thickness and echogenic appearance of the gall bladder wall. Normal bile duct.



PATIENT

Stella Shaw

SPECIES

Canine

BREED

DSH

SEX

Intact Female

AGE

7½ years

WEIGHT

105 #

INTERPRETED BY

Remo Lobetti, BVSc,
MMedVet (Med),
PhD, Dipl. ECVIM

IMAGING PERFORMED BY

Lara Wiseman, DVM

HOSPITAL NAME

Boca Midtowne
Animal Hospital

REFERRING VET

Dr Boazman

INVOICE

302929

DATE

4/27/22

Gastrointestinal

Normal appearance of the gastro-esophageal junction, stomach, duodenum, small intestine, ileo-cecal junction, and colon with no loss of layering, normal wall thickness (duodenum 0.46 cm, jejunum 0.41 cm) and peristalsis, and no distension of the lumen.

Pancreas

Normal size (right 2 cm) and echogenic appearance. Regular capsule. Normal echogenic appearance of the mesentery and fat surrounding the pancreas.

Free Abdomen

No mesenteric lymphadenomegaly.
No ascites.

ULTRASONOGRAPHIC FINDINGS

Primary findings:

- Uterine fluid accumulation.

Secondary findings:

- None.

INTERPRETATION OF THE FINDINGS & FURTHER RECOMMENDATIONS

Etiologies for the uterus would be recent estrus, mucometra, emerging endometrial hyperplasia, and early pyometria.

Further assessment/therapy needs to be based on the pending results but could include FNA cytology of the popliteal lymph nodes, vaginoscopy, and with the presenting clinical signs, endoscopy of the upper GI tract with biopsies.



PATIENT

Stella Shaw

SPECIES

Canine

BREED

DSH

SEX

Intact Female

AGE

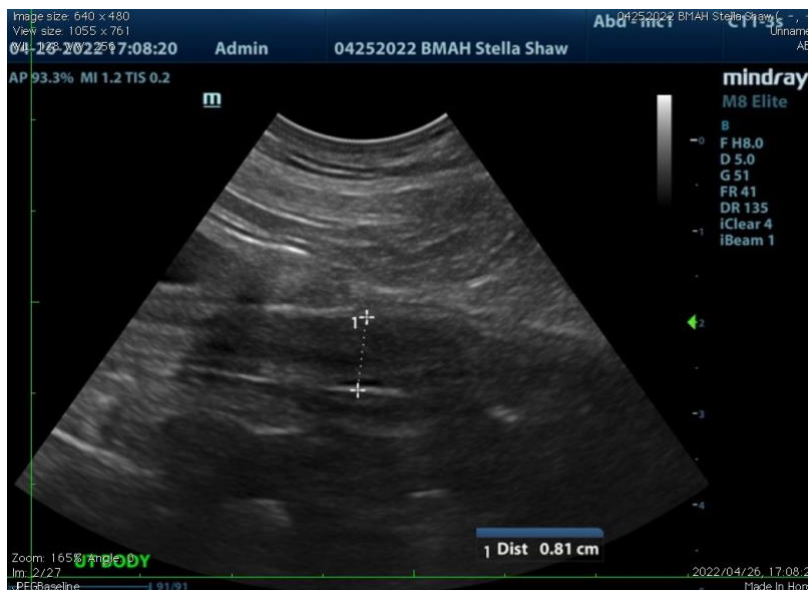
7½ years

WEIGHT

105 #

IMAGES

Uterus



INTERPRETED BY

Remo Lobetti, BVSc,
 MMedVet (Med),
 PhD, Dipl. ECVIM

IMAGING PERFORMED BY

Lara Wiseman, DVM

HOSPITAL NAME

Boca Midtowne
 Animal Hospital

REFERRING VET

Dr Boazman

INVOICE

302929

DATE

4/27/22

The information and recommendations provided are based on the images presented by the referring veterinarian. No evaluation can be communicated regarding pathology that was not visible in the image/video clips provided.

Thank you for this referral. If the clinical or image interpretation does not parallel your findings or if I can be of any further assistance please contact me.

Remo Lobetti, BVSc, MMedVet (Med), PhD, Dipl. ECVIM (Internal Medicine)
 rlobetti@mweb.co.za